

CHAPTER 28

Pre-formed Donor-Specific Alloantibodies (DSA) Detected Only by Luminex Technology Using HLA-Coated Microspheres and Causing Acute Humoral Rejection and Kidney Graft Dysfunction

Manuel Muro,¹ Santiago Llorente,² Maria J. González-Soriano,² Alfredo Minguela,¹ Luisa Gimeno,² and María R. Álvarez-López¹

Departments of ¹Immunology and ²Nephrology, University Hospital Virgen de la Arrixaca, Spain

INTRODUCTION

Classically, sensitization is defined as the presence of pre-formed alloantibodies (usually anti-HLA class I antibodies but sometimes anti-HLA class II or non-HLA antibodies as well) in the serum of a prospective transplant recipient. Sensitization is measured by testing the patient's serum for cytotoxicity against a panel of lymphocytes with various HLA types. The donor vascular endothelium is the major target of alloantibody, particularly the microcirculation. The target organ is destroyed by the ability of donor-specific antibodies (DSA) to recruit effector systems including complement, leukocytes including neutrophils, natural killer cells, and macrophages (1). Thus, a positive T-cell cross-match is an absolute contraindication to transplantation because of the risk of hyperacute rejection and immediate graft dysfunction and loss. Indeed, alloantibodies not only may cause hyperacute rejection, the most severe type of humoral graft injury, but also may contribute to other types of rejections, such as acute or chronic rejection (2,3).

This work presents a very interesting clinical case with respect to pre-sensitization of a patient and the different methods used to analyze this sensitization which, when not

properly detected, may play an important role in the outcome of a clinical transplant.

CASE

A 45-year-old woman with end-stage renal disease (renal polyquistosis) was transplanted in our hospital. Four years before admission, the patient's base-line creatinine concentration began rising from her usual level of 3.4 mg per deciliter; three and a half years before admission, renal failure occurred and hemodialysis was begun. There was no history of chest pain, dyspnea, cough, fever, or vomiting. The patient did not use tobacco, alcohol, or illicit drugs. Tests for hepatitis B surface antigen and for antibodies to hepatitis C were negative, as was a serologic test for VIH, although antibodies to cytomegalovirus were positive.

She was apparently not sensitized to HLA antigens and had a panel-reactive antibody (PRA) level approaching 0% by standard complement-dependent cytotoxicity (CDC) technique; she was also without previous transfusion history and transplants (with inclusion into the waiting list 3 year ago). Before transplantation, cross-matching of the patient's serum and the donor's T- and B-cells by standard CDC as-

say was negative. This cross-match test (with extended times for more sensitivity) was performed as previously published (4,5).

On the evening of admission, transplantation of a left cadaveric kidney into the left iliac fossa was performed without incident, except that endarterectomy of the left common iliac artery was necessary before creation of the anastomosis; the transplantation then became pink, and a left popliteal pulse was palpable. The flow of urine was sluggish until furosamida, mannitol, and fluid were infused.

On the post-transplant hospital days, prednisone, dopamine, albumin, mycophenolate mofetil, ranitidine, and tacrolimus were given.

On the second hospital day, two units of packed red cells were transfused, and ecography was apparently normal, although initial oliguria persisted despite the administration of furosamide and mannitol. There was no hydronephrosis. Doppler evaluation of the renal artery showed that the resistive index (RI) was slightly elevated (0.78), and no perinephric collection of fluid was identified.

On the third hospital day, radionuclide scanning indicated that perfusion of the transplanted kidney was severely reduced, with a parallel decrease in renal function manifested as impaired uptake and clearance of tracer activity. Doppler evaluation showed that the RI was more elevated (1.0), indicating that diastolic flow in the transplanted kidney is poor.

The next day, surgical exploration revealed a well-perfused allograft that appeared healthy but felt soft; a wedge biopsy was obtained. In the examination of the frozen sections, the patient presented facts that were strongly suggestive of acute humoral rejection, as published (6,7). Humoral (or antibody-mediated) rejection is characterized by an aggregation of neutrophils in the peritubular capillaries and glomeruli, fibrin thrombi in the capillaries, vasculitis, and occasional fibrinoid necrosis of the vessel

walls. Moderate focal interstitial edema and clusters of tubules lined by flattened epithelium indicated tubular injury without thrombosis. The next day, plasmapheresis and 3 boluses of methylprednisolone (500 mg per bolus) treatment were begun, and surgical exploration revealed a globular allograft that maintained conserved arterial and venose flow.

On the seventh day, due to a decreased hematocrit, two units of packed red cells were transfused, and echography indicated perirenal hematuria and abdominal pain. Surgical procedure showed a violet graft with a thrombosed vein and perirenal bruise; thus the kidney allograft was removed.

Post-transplantation cross-match by CDC assay with serum drawn at the time of the first biopsy was strongly positive, as would be expected in a case of acute humoral rejection; CDC (PRA = 53.2%), ELISA (GTI Diagnostic, Waukesha, WI) (PRA = 61.2%) and FlowPRA (OneLambda, Inc., CA) (PRA = 68.3%) antibody screenings were also performed. FlowPRA microparticle evaluations were administered according to the manufacturer's recommended procedures, as previously published (5). ELISA and FlowPRA methods also detected antibodies that are not cytotoxic in a standard CDC (i.e., non-complement-fixing antibodies). This latter assay also showed that these detected antibodies were anti-immunoglobulin G (IgG) antibodies. Indeed, we detected an anti-A2 antibody in this screening (the donor's typing had A2) in high titer. Then we performed ELISA and FlowPRA screening in the pre-transplant sera and received similarly negative results, confirming the previous pre-transplantation CDC screening. Figure 1 shows the comparison between pre- and post-transplantation FlowPRA determination. In view of these conflicting results and due to the new luminex technology available in our laboratory (Labscreen, OneLambda), we applied it and found in the pre-transplant sera anti-A2 and anti-B7 antibodies in low titer, which had not been detected with CDC, ELISA, and FlowPRA technologies.

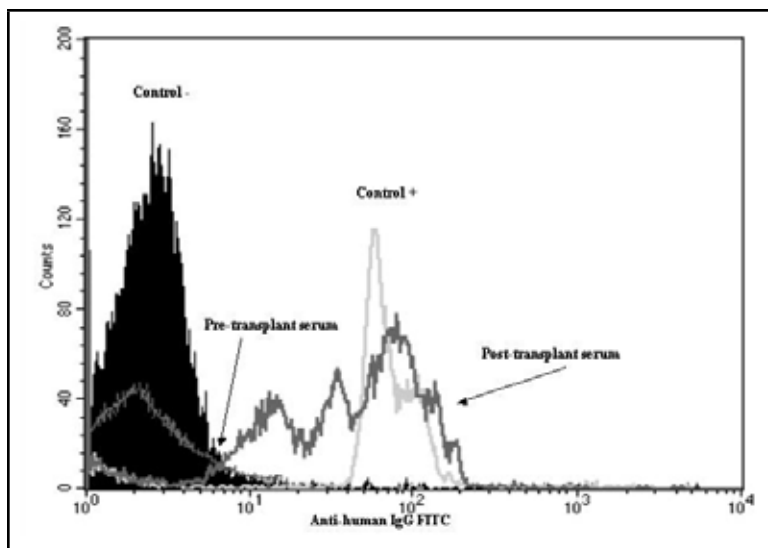


Figure 1. FlowPRA screening in pre- and post-transplant sera in our patient. The histograms show the presence of IgG antibodies in the post-transplant serum and the absence in the pre-transplant serum.

Table 1. HLA Class I and II Typing of the Patient, Organ Donor, Husband, and Sons

	HLA			
	Locus A	Locus B	Locus DRB1	Locus DQB1
Patient	A23, A32	B8, B44	DRB1*07, *13	DQB1*02, *04
Organ Donor	A2, A29	B8, B44	DRB1*03, *07	DQB1*02, *02
Husband	A2, A2	B7, B44	DRB1*04, *15	DQB1*03, *06
First Son	A2, A23	B7, B8	DRB1*13, *15	DQB1*06, *06
Second Son	A2, A23	B7, B8	DRB1*13, *15	DQB1*06, *06
Third Son	A2, A23	B8, B44	DRB1*04, *13	DQB1*04, *03

Therefore, we performed familiar typing on the patient's sons (the patient had three sons and two abortuses; her last pregnancy was 17 year ago). HLA-A and -B class I antigens were determined using the standard micro-lymphocytotoxicity technique (4,8). HLA-DRB1 and -DQB1 genotyping were performed by the PCR-SSP method (One Lambda), as previously published (9).

HLA class I and II typings of the patient, donor, husband, and sons are summarized in Table 1. Two of the patient's sons presented A2, B7, DR15, and DQ6 mismatches, while their mother and the other son presented A2, DR4, and DQ8 mismatches. Indeed, cross-matching of the patient's pre-transplant serum and the son's and husband's T- and B-cells by standard CDC assay was negative, and the post-transplant serum was positive.

Thus, sensitization of the patient was probably caused by previous exposure to alloantigens such as multiple pregnancies and deliveries with exposure to paternal HLA antigens expressed by fetal cells. These alloantibodies are directed against class I and II molecules, generally as high-affinity IgG. The patient probably had low titers of pre-transplant anti-donor antibodies that were not detected prospectively by the lymphocytotoxicity and flow cytometry assays. These antibodies were retrospectively detected by luminex technology when the patient had graft loss, but they might have been detected before transplantation.

DISCUSSION

For more than 30 years, the CDC assay has been standard for the detection of preformed anti-HLA antibodies in the sera of potential kidney transplant recipients. This assay has been criticized for not being able to detect non-complement binding, low affinity, or low titer antibodies. However, the clinical relevance in kidney transplantation of additional antibodies detected by the more sensitive ELISA and flow cytometry techniques is a matter of debate

(2,3,10). In this sense, there are other articles comparing the different methods of HLA antibodies screening (11), although there are limited articles in which the clinical relevance and consequences of these comparisons are clear and manifest. The present article shows a clear difference between these methods, and this difference is of major clinical importance; in our case, only the luminex technology was able to identify the patient's antibodies, and these were strongly deleterious for allograft outcome.

Although antibody-mediated rejection is associated with increased graft loss (1), recovery of renal function can generally be achieved with aggressive early treatment. The important purpose of all therapeutic modalities is the removal of alloantibodies or the control of their production. The attractive treatment of early antibody-mediated rejection is the removal of alloantibodies by plasmapheresis or immunoadsorption with or without the immunosuppressive agents. However, this type of treatment was not sufficient to avoid the graft loss suffered by our patient.

Another curious point of this clinical case is that the patient had circulating antibodies, which were the result of a sensitizing event that occurred 17 years ago; these antibodies in low titer could produce an immune response conducive to graft failure in spite of immunosuppressive regimen. In patients with pre-existing and long-standing alloantibody responses, however, immunosuppressives

may have little effect, possibly due to long-lived plasma cells (1). The longevity of antibody responses is maintained by the presence of these long-lived plasma cells or by the persistence of antigen. Long-term antibody responses, however, are maintained by non-dividing, long-lived plasma cells that produce high-affinity antibody and reside mainly in the bone marrow. Survival of long-lived plasma cells is regulated by the competition of limited survival niches. Once in survival niches, the persistence of long-lived plasma cells does not require the presence of antigen (12). In our case, the presence of low-titer antibodies in the recipient or the activation of memory B cells could have mediated these facts since IgG antibodies were present. In this sense, following transplantation, exposure to antigen can stimulate memory cells, resulting in an amnestic response and rapid production of anti-HLA antibodies. Indeed, in rejection, the strong INF- γ production in the graft ensures high MHC expression and allows IgG alloantibodies to effectively activate complement (1).

On the other hand, this case report underlines the importance both of identifying patients who are sensitized by using several screening methods and of cross-matching with historical sera. At least some antibody-mediated rejection can probably be prevented by very sensitive screening and cross-matching methods. Indeed, luminex technology has recently been noted as more sensitive than other techniques for antibody detection (13).

SUMMARY

The different methodologies for the detection of HLA sensitization could have discrepant results. At the moment, luminex technology seems — in our opinion — to be the most sensitive and safest method for antibody de-

tection, and it should be taken into account during the transplantation process and as a means of indicating immunosuppressive regimen modulation.

REFERENCES

1. Vongwiwatana, A., Tasanarong, A., Hidalgo, L.G., and Halloran, P. The role of B cells and alloantibody in the host response to human organ allografts. *Immunol Rev* (2003); 196: 197–218.
2. Susal, C. and Opelz, G. Kidney graft failure and pre-sensitization against HLA class I and class II antigens. *Transplantation* (2002); 73: 1269–1273.
3. Terasaki, P.I. and Ozawa, M. Predicting kidney graft failure by HLA antibodies: a prospective trial. *Am J Transplant* (2004); 4: 438–443.
4. Ontañón, J., Muro, M., García-Alonso, A.M. et al. Effect of partial HLA-class I match on acute rejection in viral pre-infected human liver allograft recipients. *Transplantation* (1998); 65: 1047–1053.
5. Muro, M., Sánchez-Bueno, F., Marín, L. et al. Relationship between CDC cross-match in liver recipients and antibodies screening by flow cytometry. *Transplant Proc* (2003); 35: 1894–1895.
6. Böhmig, G.A., Exner, M., Habicht, A. et al. Capillary C4d deposition in kidney allografts: a specific marker of alloantibody-dependent graft injury. *J Am Soc Nephrol* (2002); 13: 1091–1099.
7. Sayegh, M.H. and Colvin, R.B. Case 8 (2003): a 35-year-old man with early dysfunction of a second renal transplant. *N Eng J Med* (2003); 348: 1033–1044.
8. Muro, M., Marín, L., Torío, A. et al. HLA polymorphism in the Murcia population (Spain) in the cradle of the archaeological Iberians. *Hum Immunol* (2001); 62: 910–921.
9. Muro, M., Álvarez-López, M.R., Torío, A. et al. HLA-DRB1 and -DQB1 polymorphism in liver recipients: relationship between HLA-DQB1*0302 allele frequency and acute rejection. *Hum Immunol* (1997); 56: 70–76.
10. Fernández-Fresnedo, G., Pastor, J.M., López-Hoyos, M. et al. Relationship of donor-specific class-I anti-HLA antibodies detected by ELISA after kidney transplantation on the development of acute rejection and graft survival. *Nephrol Dial Transplant* (2003); 18: 990–995.
11. Dyer, P.A., Taylor, C., and Martin, S. “HLA and clinical solid organ transplantation: recent publications and novel approaches.” *HLA* (1998); 13–45.
12. Slifka, M.K., Antia, R., Whitmire, J.K., and Ahmed, R. Humoral immunity due to long-lived plasma cells. *Immunity* (1998); 8: 363–372.
13. Pretl, K., Chesterton, K.A., Scholander, J.T., Leffell, M.S., and Zachary, A.A. Accurate, rapid characterization of HLA-specific antibody using luminex technology. *Hum Immunol* (2003); 64: S108.

